

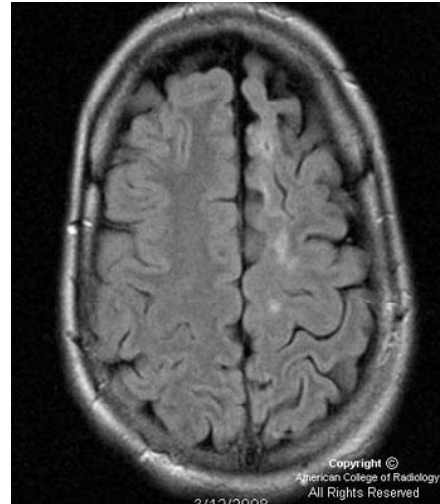
Picture quiz

Epilepsy

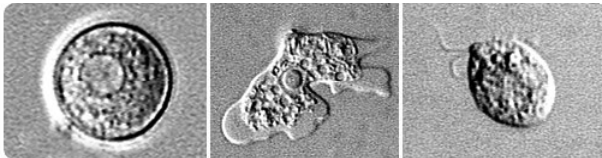
Sri Lanka Journal of Neurology, 2012, 1, 57



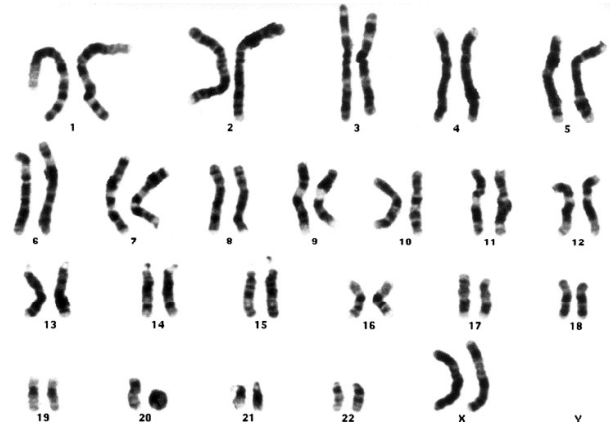1. This 5-year old girl has epilepsy and learning disability. What is the diagnosis?



3. This 12-year old boy has intractable epilepsy and a hemiparesis. What is the diagnosis?



2. This organism is a cause of seizures and encephalitis and death seen in Pakistan and India. What is the organism?



4. This chromosome study is from a child who has epilepsy and minor learning disability. What is the diagnosis?

(Answers on page 61)